

Chinese White Dolphin suffers horrendous injuries inflicted by boat's propeller

Reported on 18 January 2015

Shortly before the evening approached last Friday, a severely injured Chinese White Dolphin was seen off Tai O peninsula. The dolphin was first spotted by Mr. Simon Wong, a PhD student at the School of Biological Sciences, The University of Hong Kong and member of Cetacean Ecology Lab at The Swire Institute of Marine Science (SWIMS). Mr. Wong and his colleague Mr. John Kwok were scanning coastal waters from the top of the hill above the Tai O village, when they saw the dolphin struggling while trying to swim. It was shortly after 16:00 at the time.

After a quick consultation regarding the type and severity of the injuries with Dr. Leszek Karczmarski, the Head of the Cetacean Ecology Lab at SWIMS, Mr. Wong contacted the Marine Mammal Response and Rescue team at Ocean Park, while Dr. Karczmarski informed the Agriculture, Fisheries and Conservation Department (AFCD) and called for a rescue operation to be launched. Several boats went in search of the dolphin, including the research vessel operated by the Cetacean Ecology Lab, the Marine Park's boat and Marine Police. However, the injured animal was not found as the night approached.

On Saturday afternoon, the injured dolphin was spotted again off Tai O shortly after 16:30 by both the researchers from the SWIMS's Cetacean Ecology Lab and the team from Hong Kong Dolphin Conservation Society. This time the animal was close to the breakwater inside the Tai O Bay.

Dr. Karczmarski, Associate Professor at HKU's School of Biological Sciences and Research Scientist at The Swire Institute of Marine Science, explained that the dolphin was evidently seeking a shelter in the calmer waters inside the Tai O Bay.

Dr. Karczmarski said that the photographs and video footage collected by his research team shows the dolphin has a multiple deep cuts on its back. The cuts are so large that they were already evident the day earlier, on Friday, when Mr. Wong and Mr. Kwok observed the dolphin from the shore, some 500 m away from the animal. These are propeller cuts, says Dr. Karczmarski, and one can see that the initial cuts were done just behind the dorsal ridge of the dolphin, and when the animal tried to escape further injury by making a deep dive, it received the final most severe blow that cut through its muscles on the upper peduncle (the tail of the dolphin). This final cut, just at the base of the dolphin's fluke, is very severe and may decide the animal's fate.



Photo: © Cetacean Ecology Lab, The Swire Institute of Marine Science, HKU

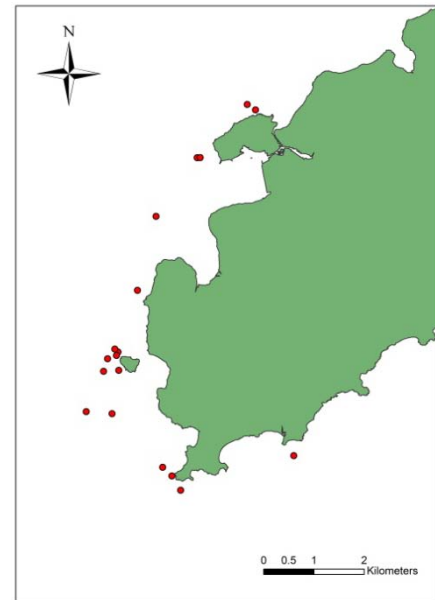
Severely injured Chinese White Dolphin, first seen in the evening of 16 January 2015 off Tai O peninsula. The photograph to the left depicts the animal seen the following day, 17 January inside Tai O Bay.

Mr. Stephen Chan, a PhD student who is investigating dolphin population process under Dr. Karczmarski's supervision at HKU, noted that one of the photographs posted on Saturday in Apple Daily by the Hong Kong Dolphin Conservation Society show the animal with patches of mud in front of his dorsal fin, while it was not on some other photographs and the photos taken by the HKU research team. This indicates that the dolphin can still dive to the bottom and turn upside down, Mr. Chan says, as dolphins often do when foraging in Hong Kong murky waters.

This animal is well known to the SWIMS-HKU research team. Ms. Carmen Or, a PhD student and member of SWIM's Cetacean Ecology Lab who studies dolphin socio-ecology and habitat use under the supervision of Dr. Karczmarski, says that the animal is a young male that has been seen for the past five years, since mid-2010, mostly off southwest Lantau, between Tai O and Fan Lau. She compiled a map of the sighting records of this individual.

The injured dolphin is well known to the researchers from HKU's Cetacean Ecology Lab. The animal has been seen frequently in waters of SW Lantau. The map to the right depicts the sighting since mid-2010.

Map: © Ms. Carmen Or, Cetacean Ecology Lab, The Swire Institute of Marine Science, HKU



The animal was seen again near Tai O on Sunday morning. The fact that the animal managed to survive at least a day-and-a-half since first seen with such horrendous injuries, indicates that this is a strong individual, says Dr. Karczmarski. As any animal in distress, it has attempted to find a shelter in the calmer waters deeper in Tai O Bay, and it is important that the animal not be harassed by casual observers. However, it is highly unlikely that the dolphin can survive such severe injury if not given medical help. The damage to the muscles on its upper peduncle means that the dolphin does not have the muscular support to swim efficiently and catch its food. It may occasionally capture a fish here and there, but it would be far insufficient to support the energetic demands of a grown dolphin. Dr. Karczmarski fears that the deep cut through the peduncle at the base of the fluke may have been deep enough to cause injury to the dolphin's backbone. The multiple open wounds will likely soon be infected, which might cause further suffering of the dolphin.

A swift rescue operation is needed, Dr. Karczmarski says. He differs in this opinion from Dr. Samuel Hung of Hong Kong Dolphin Conservation Society, who urged that the dolphin be left alone and not disturbed. Hung says he "hopes that the dolphin will make it through this extremely difficult time."

Dr. Karczmarski, who teaches the Biology of Marine Mammals and Animal Behaviour at the University of Hong Kong, is of a different opinion. He says that the severity of the injuries and the current behaviour of the dolphin indicate that the animal is under tremendous stress, both physiologically and behaviourally. Dolphins are social animals and depend of the group support for their daily needs. The injured animal is on its own, which indicates that he cannot keep up with its group. It seeks shelter and is unable to move swiftly enough to sustain its foraging and nutritional needs. Its health may soon be compromised by infection. It needs medical attention, as otherwise it will likely die a long and painful death, Dr. Karczmarski says.

The dolphin can and should be rescued, Dr. Karczmarski pointed out very strongly. It should not be abandoned and left to its own misery under such horrific circumstances, he says. He indicated that Ocean Park has suitable rehabilitation facilities and can provide high quality veterinarian care, and that a swift action should be arranged to capture the animal and take it under intensive medical care. The chance of rescuing and rehabilitating the injured dolphin is worth the short-term stress that the capture operation will cause, he says.

It is one of the most severe dolphin injuries I have ever seen, says Dr. Karczmarski, but evidently we are dealing with a tough animal that has made it though the most horrendous of it. But he needs our help and care, and he needs it very urgently, Dr. Karczmarski adds.

Recent study by SWIM's Cetacean Ecology Lab shows that almost 4% of dolphins in Hong Kong bear wounds that are inflicted by either collisions with boats or entanglement in fishing gear; while another 5% have varied degrees of skin disorders, likely effects of pollutants and pathogens present in Hong Kong waters.

To learn more about the Cetacean Ecology Lab at the Swire Institute of Marine Science, visit the website: <http://www.hku-cetacean-ecology.net/>

